


## Postablation Endometrial Carcinoma

[Morris Wortman](#), MD,  [George A. Vilos](#), MD, [Angelos G. Vilos](#), MD, [Basim Abu-Rafea](#), MD, [Wendy Dwyer](#), MD, and [Robert Spitz](#), MD

Morris Wortman, The Center for Menstrual Disorders, Rochester, New York, USA and Clinical Associate Professor of Obstetrics and Gynecology University of Rochester School of Medicine.

[Contributor Information](#).

 Corresponding author.

Disclosures: None reported.

Address correspondence to: Morris Wortman, MD, The Center for Menstrual Disorders, 2020 South Clinton Avenue, Rochester, NY 14618, USA. Telephone: [585-473-8770](tel:585-473-8770), Fax: [585-473-8853](tel:585-473-8853), E-mail: [Moe2020@cmdrc.com](mailto:Moe2020@cmdrc.com)

[Copyright](#) © 2017 by JLSLS, Journal of the Society of Laparoendoscopic Surgeons.

This is an Open Access article distributed under the terms of the Creative Commons Attribution Non-Commercial No Derivatives License (<http://creativecommons.org/licenses/by-nc-nd/3.0/us/>), which permits for noncommercial use, distribution, and reproduction in any medium, provided the original work is properly cited and is not altered in any way.

### Abstract

[Go to:](#) 

#### Background:

Many women have undergone both resectoscopic and nonresectoscopic (or global) endometrial ablation (EA) during the past 20 years. These women are now approaching their sixth and seventh decades of life, a time frame in which endometrial carcinoma (EC) is most frequently diagnosed.

#### Database:

In several reports, surgeons have expressed concern that endometrial ablation may leave a sequestered island of EC that may escape detection, possibly delaying its diagnosis or causing it to appear at an advanced stage. Others suggest that EA artifact does not hinder the evaluation and treatment planning in the presence of EC. Data bases used are from Medline and PubMed.

#### Discussion:

We introduce 6 new cases of postablation endometrial carcinoma (PAEC), 4 of which occurred after the introduction of global endometrial ablation (GEA) techniques. In addition, we examine several key questions regarding the impact of EA on the subsequent development of EC, including the manner in which PAEC presents, the efficacy of traditional diagnostic modalities, the ablation-to-cancer interval, and the stage of PAEC at the time of diagnosis. Finally, we explore the use of reoperative hysteroscopic surgery (RHS) as a diagnostic modality and address the possible role ultrasound surveillance as a screening method for women at risk of EC.

**Keywords:** Endometrial ablation complications, Global endometrial ablation complications, Reoperative hysteroscopic surgery, Late-onset endometrial ablation failure, Ultrasound-guided reoperative hysteroscopy

## INTRODUCTION

[Go to:](#)

Endometrial ablation (EA) traces its history to 1898 when Albert Dührssen<sup>1</sup> described the first case of selective endometrial destruction in an attempt to provide relief for a 37-year-old woman “exhausted by profuse and persistent menorrhagia by introducing steam into the uterine cavity for 2 minutes.” Dührssen noted that “as a result, the uterus underwent complete atrophy.”

Following the development of electrosurgical generators Bardenheuer,<sup>2</sup> in 1937, published “Elektrokoagulation (ELK) der Uterusschleimhaut, (Electrocoagulation of the endometrium),” by introducing a unipolar electrode (Kungelsoendenelektrode) varying from 5 to 8 mm and mounted on a 12- to 16-cm shaft. In 1948 Bauman<sup>3</sup> promoted Bardenheuer's technique and reported a series of 387 women who were treated in an office setting under “light narcosis.” Bardenheuer reported a very low complication rate, but identified the first cases of late-onset endometrial ablation (EA) failure and stressed the importance of avoiding electrocoagulation of the internal os, to reduce the likelihood of hematometra formation and cyclic pelvic pain.

In the early 20th century, after Marie Curie's discovery, the use of radium attracted the interest of physicians because of its ability to affect human tissue. In 1937, Schultze<sup>4</sup> reported a series of 204 women with menorrhagia who were treated with intrauterine radium in hopes of achieving a restoration of normal cyclic menses; unlike today, amenorrhea was regarded as “overtreatment.” The application of intrauterine radium, however, was fraught with undesirable side-effects, including atrophic vulvitis, sterility, and dyspareunia, and was soon abandoned.

The next foray into EA came in 1967 when Cahan and Brockunier<sup>5</sup> reported the first attempts at cryoendometrial ablation. Droegemueller et al<sup>6</sup> described a similar technique using both Freon (DuPont, Deepwater, New Jersey, USA) and nitrous oxide probes. Despite some success, these devices proved to be costly and cumbersome and were abandoned because of the potential for producing painful hematometra.

A paradigm shift occurred when Goldrath et al<sup>7</sup> collocated the rod–lens system of a hysteroscope with a Neodymium:YAG (Nd:YAG) laser and, in 1981, reported the first cases of EA under direct visualization. Despite their success, the use of the Nd:YAG for EA never gained wide acceptance for at least 3 reasons. First, most gynecologists were unfamiliar with hysteroscopy. Second, the cost of a typical Nd:YAG laser in the mid-1980s—over \$100,000 U.S.—was prohibitively expensive. Third, the continuous-flow hysteroscope had not yet been invented, and the laser procedure posed many operative challenges.

Several years later, however, DeCherney and Polan<sup>8</sup> used a conventional urologic resectoscope to perform EA. Because DeCherney's energy source—an inexpensive monopolar electrosurgical unit—was already available in most operating rooms, one significant problem confronting hysteroscopic EA had been addressed. However, the lack of a continuous flow resectoscope limited the acceptance of DeCherney's technique.

In 1989, the U. S. Food and Drug Administration (FDA) approved the continuous-flow gynecologic resectoscope and Vancaillie<sup>9</sup> reported the first cases of EA with a ball-end electrode. The inexpensive acquisition costs and excellent visualization allowed this technique to gain some limited popularity within the gynecologic community. Although resectoscopic EA had its adherents, early reports of fatalities resulting from uterine perforation, visceral injury, and distention fluid overload were of great concern to surgeons. In 1993 Arieff and Ayus<sup>10</sup> and Baggish et al<sup>11</sup> separately reported a series of deaths attributed to hyponatremic encephalopathy, and the search for safer EA methods ensued.

An important paradigm shift in EA occurred in 1997 with the introduction of the first nonresectoscopic endometrial ablation (NREA) or “Global ablation” devices. These are often collectively called second-generation devices, a term that belies their history. Between 1997 and 2003, a total of 5 NREA devices received FDA approval: the thermal balloon (ThermaChoice Uterine Balloon System; Johnson and Johnson, New Brunswick, New Jersey, USA); the cryoablation system (Her Option; Cooper Surgical, Trumbull, Connecticut, USA); a heated free-fluid system (Hydro ThermAblator or HTA System; Boston Scientific, Natick, Massachusetts, USA); a bipolar radiofrequency ablation device (NovaSure EA; Hologic, Inc., Bedford, Massachusetts, USA); and a microwave ablation system (MEA System; previously produced by Microsulis Medical Limited, Denmead, UK). In 2015, a sixth system using radiofrequency energy and a plasma formation array (PFA) also became available (Minerva Endometrial Ablation System; Redwood City, California, USA). These systems, reminiscent of the original “blind” techniques of the early 20th century, boast 2 important advantages: their operation is easily learned and they are exceptionally safe. Global EA (GEA) techniques obviated the risks of fluid overload and hyponatremia while curtailing the incidence of the visceral injuries once associated with resectoscopic procedures.<sup>12,13</sup> These benefits enabled the growth of the U. S. global GEA market, which in 2012 entailed 390,000 procedures<sup>14</sup> valued at \$730 million.<sup>15</sup> The domestic GEA market is forecast to reach 490,000 procedures by 2017,<sup>14</sup> and, together with resectoscopic endometrial ablation (REA), may soon surpass the number of hysterectomies in the United States.<sup>16</sup>

The use of GEA devices is a major factor in the sharp decline in the incidence of immediate postablation complications, but there have been several reports of late-onset EA failures (LOEAFs)<sup>17,-20</sup> in the months and years after EA. Longinotti et al<sup>19</sup> and Munro<sup>20</sup> both noted that late-onset EA complications cause 25% of women to require hysterectomy within 5 years after undergoing EA. LOEAFs have thus far presented in 3 separate ways: persistent or recurrent vaginal bleeding,<sup>17,-20</sup> the development of cyclic pain,<sup>17,-20</sup> and the inability to adequately assess the endometrium in women who would later require its evaluation.<sup>21</sup>

The concern regarding adequate endometrial assessment was first expressed by DeCherney et al,<sup>22</sup> who in 1987 forewarned that the consequence of failing to destroy a “nest of endometrial tissue” could result in a sequestered island of endometrial carcinoma (EC) inaccessible to standard biopsy techniques, possibly delaying or obscuring the diagnosis. Subsequently, McCausland and McCausland,<sup>23</sup> AlHilli et al,<sup>24</sup> and Neuwirth et al<sup>25</sup> have echoed similar concerns.

Meanwhile, in the 3 decades since DeCherney's initial concerns, both EA and EC have evolved in the United States and other developed countries. Hologic Inc., the manufacturer of the most commonly employed GEA device,<sup>14,18</sup> reported that more than 2 million NovaSure procedures were performed between 2001 and 2014.<sup>26,27</sup> Concomitantly, the United States and many other countries are

-- --

experiencing a significant increase in the prevalence of EC,<sup>28–32</sup> largely attributable to an aging and increasingly obese population. The changing landscape of EC and the widespread adoption of EA will present looming challenges as our specialty faces a large cohort of women who have undergone EA and are about to enter their sixth and seventh decades of life—peak years for the presentation of EC.

In 2011, AlHilli et al<sup>24</sup> reviewed the English literature and reported 17 cases of postablation EC. One of the authors (MW), has since reported an 18th subject in a previous paper.<sup>32</sup> This paper will present 6 additional occurrences of PAEC and summarize our current understanding of this entity. The authors will attempt to address 4 important questions: First, how has the widespread adoption of EA affected the subsequent development of EC? Second, will PAEC present differently, compared with women who have never undergone this procedure? Third, does a history of EA present diagnostic challenges to the confirmation of EC? Fourth, do EA-treated women present at a more advanced stage compared to other women in the population? Finally, we will offer suggestions for EC surveillance based on our present but limited knowledge of PAEC, as a very large group of women who have undergone EA enter a time frame that places them at greater risk for developing EC.

The University of Rochester Research Subjects Review Board reviewed the manuscript and deemed that “the project does not qualify as human subjects research (45 CFR 46.102), in that the activities do not meet the federal definition of research.”

## CASE REPORTS

Go to:

### Case 1

The patient was a 41-year-old woman who presented with abnormal uterine bleeding (AUB) and underwent an endometrial biopsy that revealed a weakly proliferative endometrium with focal breakdown. Two months later, in June 2007, she underwent a diagnostic hysteroscopy and polypectomy immediately followed by a radiofrequency EA (NovaSure; Hologic Inc.). The histologic examination revealed a benign endometrial polyp in a background of proliferative endometrium.

The patient was seen for annual examinations and did well for nearly 7 years, until April 22, 2014, when she presented with left lower quadrant pain unaccompanied by vaginal bleeding. Ultrasonography revealed a slightly enlarged uterus (12.2 cm long × 6.6 cm anterior-posterior [AP] thickness, and 8.5 cm transverse) that contained an apparent septum, along with evidence of “endometrial thickening” in both cornual regions; a complex and multiseptated left ovarian cyst (6.4 × 4.8 × 8.1 cm) was also identified. A CA-125 drawn at the time of this evaluation was 40.8 (normal, <30). Several days later, the patient experienced an episode of vaginal bleeding accompanied by severe relapsing and remitting left lower quadrant and suprapubic pain.

The patient was referred to a gynecologic oncologist for evaluation of her left ovarian mass. On June 19, 2014, she underwent a robot-assisted left salpingo-oophorectomy and resection of a retroperitoneal mass, histologically confirmed to be an endometrioma. No attempt was made to evaluate the uterine cavity. On July 25, 2014, the patient experienced another episode of left lower quadrant pain unaccompanied by vaginal bleeding. An ultrasonogram revealed a prominent area of “endometrium” measuring 16.1 mm in AP thickness in the left fundal portion of the uterus, along with a 5.6 × 2.7-cm fluid collection within the cul-de-sac. There was also a complex right ovarian cyst that measured 4.6 × 4.9 × 3.2 cm with septations and homogeneous echoes. An endometrial biopsy was attempted on July

29, but the operator failed to gain access to the uterine cavity.

On August 25 the patient underwent an abdominal hysterectomy requiring extensive adhesiolysis. A frozen section revealed complex hyperplasia; likely atypical. The final pathology revealed an endometrioid type adenocarcinoma with mucinous and secretory features; FIGO (International Federation of Gynecology and Obstetrics) grade 1. The carcinoma involved 80% of the “endometrial surface” but demonstrated no myometrial invasion. Other histologic features included a background of atypical complex hyperplasia, adenomyosis, and leiomyomata. The right ovary contained an endometrioma, and the right fallopian tube revealed endometriosis with foci of atypical complex hyperplasia. No further treatment was found to be necessary, and the patient's cancer antigen (CA)-125 has since returned to normal.

### Case 2

In 1994 a 33-year-old woman underwent a roller-ball EA by one of the authors (GAV). The patient was seen in the ensuing years for annual examinations and reported excellent results, noting only regular monthly episodes of light bleeding and spotting.

Seventeen years later, on September 10, 2011, the patient presented for evaluation of abnormal perimenopausal bleeding. An endometrial biopsy was performed and produced “scant endometrial tissue with small, rare fragments of atypical cells, with cytologic atypia and showing focal necrosis.” She subsequently underwent a reoperative hysteroscopic surgery (RHS) on January 26, 2012, at which time the surgeon observed a narrow and distorted uterine cavity that contained endometrial lining that was described as highly suspicious for endometrial neoplasia. Her RHS procedure included a lysis of adhesions and total endomyometrial resection. A subsequent histologic analysis revealed an endometrioid adenocarcinoma, FIGO 3. On March 22, 2012 she underwent a total laparoscopic hysterectomy, bilateral salpingo-oophorectomy, and a pelvic and para-aortic node dissection. The specimen weighed 103 g and revealed no evidence of residual endometrial carcinoma in the uterus, tubes, ovaries, and lymph nodes. At this writing, she was doing well.

### Case 3

A 56-year-old para 3 patient presented to her primary gynecologist in 2000 for evaluation of bleeding after a normal menopause 4 years prior. Her history included a stage I intraductal carcinoma of the left breast requiring a mastectomy in 1991. At the time of her presentation, her BMI was 29 kg/m<sup>2</sup>, and she was otherwise healthy. The woman's primary gynecologist performed a fractional dilation and curettage that revealed “scant inactive endometrium and benign cervical tissue.” Her gynecologist also noted a bulky uterus, which was attributed to the presence of leiomyomas, and the patient was offered a hysterectomy. The subject, seeking a less invasive approach, was referred to one of the authors (GAV) for a hysteroscopic evaluation and treatment.

On January 28, 2000, she underwent a hysteroscopic endomyometrial resection and EA, at which time the uterus was reported to be quite small and mobile. The cervix was stenotic but subsequently allowed dilation to 10 mm permitting the introduction of a 26 French continuous-flow unipolar resectoscope. The endometrium was observed to be thin and normal appearing. The tubal ostia and fundus were electrocoagulated with a 5-mm rollerball electrode, while the rest of the endometrium was resected along with a small endocervical polyp. A histologic analysis of the specimen revealed only basalis-type

endometrium and myometrium without significant abnormalities.

The patient did well and remained amenorrheic until 2005, when she presented with pelvic discomfort and pain unaccompanied by vaginal bleeding. A transvaginal sonogram revealed a slightly enlarged uterus with multiple leiomyomas. There was no evidence of a hematometra, and no attempt was made to perform a diagnostic hysteroscopy or endometrial biopsy. Instead, the patient was scheduled for a hysterectomy and bilateral salpingo-oophorectomy. At the time of the laparotomy there was a solid mass arising from the right ovary that was densely adherent to the right pelvic sidewall and to the rectosigmoid.

The pathologic specimen (115 g, including a 10.0 × 4.5 × 4.6-cm uterus) contained a mixed EC with 50% described as undifferentiated and 50% serous. There was a 50% invasion into the myometrium, deep invasion into the endocervical stroma, diffuse lymphovascular invasion, and metastatic disease identified in the right ovary (stage III). On January 26, 2010, she underwent a right mastectomy for a carcinoma of the breast. At the time of this report she was alive and well.

#### Case 4

A patient 45-year-old mother of 4 underwent a thermal balloon EA (ThermaChoice II; Johnson and Johnson, Inc.) on October 26, 2006. An endometrial curettage performed just before her procedure revealed proliferative endometrium.

Ten years after surgery, at age 55, she experienced an episode of postmenopausal bleeding and was referred to one of the authors (GAV) for management. The patient's medical problems included hypertension and hypothyroidism, for which she was taking appropriate medications. Her BMI was 24 kg/m<sup>2</sup>. On pelvic examination, the uterus was normal size, mobile, and without adnexal enlargement. Transvaginal sonography suggested a bicornuate uterus with a 1.4-cm subendometrial leiomyoma abutting the endometrial surface near the left cornua. The endometrial thickness varied from 7 to 8 mm. Both ovaries were identified and described as normal appearing. A Papanicolaou test revealed atypical glandular cells of endometrial origin.

An endometrial biopsy was performed and revealed a well-differentiated endometrioid adenocarcinoma FIGO grade 1 with mucinous differentiation. The patient underwent a laparoscopic-assisted vaginal hysterectomy and bilateral salpingo-oophorectomy in August 2016. On histopathologic analysis, the uterus weighed 66.2 g and contained an endometrioid adenocarcinoma variant with mucinous differentiation (FIGO grade 1); there was less than 50% myometrial invasion.

#### Case 5

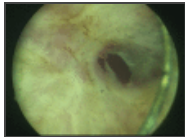
The patient, a 42-year-old gravida 3 para 3, underwent an EA with a glycerine-filled thermal balloon ablation device (Thermablate EAS; System Indoman Ltd., Toronto, Ontario, Canada) in 2007 for abnormal uterine bleeding. An endometrial biopsy performed a year before her procedure revealed proliferative endometrium. After her EA the patient experienced monthly episodes of spotting and was quite satisfied with the results.

In 2013, however, she began experiencing irregular menses associated with pelvic pain. Ultrasonography performed on December 8, 2014, revealed an enlarged uterus measuring 13.3 × 6.2 × 8.0 cm with an inhomogeneous myometrium containing a 4.6 × 4.3-cm area consistent with



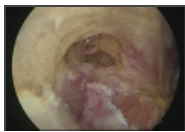
adenomyosis. The endometrium was described as irregular appearing with a thickness of 1.9 mm. On May 8, 2015, her primary gynecologist performed a diagnostic hysteroscopy and described an irregular uterine cavity with polypoid endometrium and vascular polyps. An endometrial curettage was performed but the specimen did not identify any endometrial tissue, and the patient was subsequently referred to one of the authors (GAV).

The patient presented on October 5, 2015. Now, at age 50, her medical history included sleep apnea, hyperlipidemia, and impaired glucose tolerance. On November 12, 2015, she underwent a RHS including endomyometrial resection and myomectomy. During the procedure a narrow area was identified just beyond the internal os that opened into a larger and sequestered cavity (**Figures 1, 2**) containing endometrium that was described as thick, polypoid, and consistent with malignancy. The area was resected in its entirety, together with a 2-cm leiomyoma. The tissue specimen, measuring 3.4 × 4 cm, was reported to contain a well-differentiated endometrioid adenocarcinoma (FIGO 1) in a background of atypical hyperplasia; foci suspicious for microinvasion were also identified. On January 12, 2016, she underwent a laparotomy, total hysterectomy, and bilateral salpingo-oophorectomy with peritoneal washings. The 250-g specimen contained focal residual endometrioid adenocarcinoma (FIGO 1) at the fundus, with no evidence of myometrial invasion, and no other evidence of malignancy. The patient was doing well at the time of this report.



[Figure 1.](#)

Example of sequestered endometrial cancer after endometrial ablation located at the right cornua. Adhesions obscuring access to the right cornua area.



[Figure 2.](#)

Appearance of right cornua after adhesiolysis exposing a well-differentiated adenocarcinoma of the endometrium along the right posterior surface.

## Case 6

A 49-year-old para 2 patient underwent a NovaSure EA on July 2, 2009. Her preoperative evaluation included transvaginal ultrasonography that revealed an enlarged uterus measuring 13.7 × 6.4 × 9.3 cm and containing 3 leiomyomas varying from 1.3 to 3.1 cm in greatest dimension; an endometrial biopsy revealed early secretory endometrium. A diagnostic hysteroscopy was not performed at the time of the NovaSure procedure. The patient enjoyed excellent results, including light cyclic menses until menopause in 2013. She later admitted to using an over-the-counter progesterone cream for an unspecified period of time to remedy her menopausal hot flashes and apparently achieved good results.

On April 17, 2015, the patient—now 54 years old—was seen by her primary gynecologist for an annual examination. She reported some diminished vaginal lubrication and was counseled regarding the possible use of estradiol vaginal cream which she eventually began administering in October 2015. On March 8, 2016, she reported an episode of postmenopausal bleeding, discontinued any further exogenously administered estrogen, and contacted her gynecologist (RS).

A transvaginal ultrasound examination revealed an intramural fundal leiomyoma measuring 3.2 × 2.6

cm. In addition, there was a 9 × 11 mm echogenic area located within the uterus. The subject underwent a diagnostic hysteroscopy on April 8, 2016, during which RS reported entry into the lower uterine segment where dense intrauterine adhesions were identified. A small opening was detected in the lower uterine segment but was insufficient to allow the passage of even a 5-mm hysteroscope. A smaller diameter hysteroscope and biopsy instrument were eventually passed into the left side of the uterus permitting selected endometrial biopsies. A histologic analysis of the specimen revealed a mixed carcinoma consisting of a low-grade endometrioid adenocarcinoma and a high-grade carcinoma with neuroendocrine differentiation.

On April 2, 2016, the patient underwent a total hysterectomy with bilateral salpingo-oophorectomy and periaortic and pelvic lymphadenectomy. The uterus was reported to contain minimally invasive mixed carcinoma (<50%), consisting of low-grade endometrioid adenocarcinoma (FIGO 1) admixed with a high-grade carcinoma with neuroendocrine differentiation. The fallopian tubes, ovaries, and lymph nodes revealed no signs of metastases.

All the patients have provided consent for their cases to be published.

## RESULTS

Go to:

The mean age of subjects in this series at the time of their original EA procedure was 44.3 years (95% CI 47.9–58.0), and the mean age at the time of their EC diagnosis was 53.6 years (95% CI 47.9–58.3). The average interval from EA to the diagnosis of EC was 8.8 years (95% CI 4.2–13.5). Four of the subjects had undergone a previous GEA procedure, and the remaining 2, a resectoscopic procedure. Pelvic pain was an important feature in 3 of the women and the only symptom in 2 of the 6.

Traditional office-based endometrial biopsy was successfully performed in only one of the subjects (case 4) and was never attempted in another subject (case 3). An endometrial biopsy attempt in patient 1 failed. In patients 2 and 5, a reoperative hysteroscopic technique with a resectoscope was used, while a small diameter hysteroscope was necessary to gain access to a sequestered area of endometrium to establish the diagnosis in patient 6. Five of the 6 patients (83.3%) were diagnosed with stage I EC. The results are summarized in [Table 1](#).

Case #	Age at EA	EA Procedure	With Features
1	48	Hysteroscopy	None
2	50	Reoperative hysteroscopy	Obesity
3	50	Reoperative hysteroscopy	Obesity
4	51	Endometrial biopsy	Obesity
5	51	Reoperative hysteroscopy	Obesity
6	51	Reoperative hysteroscopy	Obesity

[Table 1.](#)

Summary of PAEC Case Reports

## DISCUSSION

Go to:

EC is the most common gynecologic malignancy in the United States and affects 2.8% of women—slightly greater than for other developed countries.<sup>28,31</sup> Abnormal uterine bleeding, most often postmenopausal, is the presenting symptom in 75 to 90% of subjects with EC.<sup>29</sup> The known risk factors for EC include obesity, hypertension, diabetes, nulliparity, a history of breast cancer, and tamoxifen use.<sup>33,35</sup> The American Cancer Society predicts 60,050 new cases of EC in 2016 with 10,470 deaths attributable to the disease.<sup>31,36</sup> Between 1988 and 2012 the incidence of EC in the United States increased by 18%—from 23.6 to 27.8 per 100,000 population<sup>29,31,36</sup>—a rise generally attributable to an aging population and increasing obesity rates.<sup>28,30</sup> The average age at the time of



diagnosis is 62 years with 75.8% occurring beyond the age of 55.<sup>29,31,36</sup> Fortunately, most women with uterine cancers are diagnosed at an early stage with 67% confined to the uterine corpus. Another 21% of ECs present with spread to regional organs and nodes while 8% involve distal metastases. The overall 5-year survival rate of EC is 81.7%.<sup>29,31,36</sup>

In 1993 Copperman et al<sup>37</sup> described the first case of PAEC in a 56-year-old woman who presented with postmenopausal bleeding 5 years after a resectoscopic EA. Her evaluation permitted an endometrial biopsy revealing a moderately well-differentiated (FIGO 2) adenocarcinoma. In 1995 Margolis et al<sup>38</sup> reported the earliest case of an asymptomatic PAEC in a 58-year-old woman 3 years after an REA. The report was disquieting, inasmuch as the stage I FIGO grade 1 adenocarcinoma of the endometrium was discovered only as an incidental finding after a procedure for urinary stress incontinence. In 2011, AlHilli et al<sup>24</sup> reviewed the English-language medical literature and identified 22 cases of PAEC, of which 17 were available for analysis. Fifteen of the subjects underwent REA whereas 2 had undergone a GEA procedure: one had a prior ThermaChoice (Gynecare Inc.) and another had a NovaSure EA (Hologic Inc., Bedford MA). The mean age at the time of EC diagnosis was 54.4 years (95% CI 9.9; 49.7–59.2) with an ablation-to-cancer interval varying from 6 months to 10 years. Thirteen of the cancers (76.5%) were detected at stage I. Many of the subjects contained in AlHilli's report included women with significant EC risk factors, including obesity (64.7%), diabetes (29.4%), and endometrial hyperplasia (41.2%). Of the 7 subjects with a preablation endometrial hyperplasia, 1 had simple hyperplasia, 3 had adenomatous (complex) hyperplasia, 2 had atypical complex hyperplasia, and 1 was reported to have severe hyperplasia. Arguably, many of these women would currently be considered inappropriate candidates for EA.

Since AlHilli's review, one of the authors (MW) has reported a case of Stage I FIGO 1 PAEC in a 40-year-old woman with no identifiable EC risk factors, who had undergone a NovaSure EA 2 years earlier and presented with severe cyclic pelvic pain associated with mild vaginal spotting.<sup>32</sup> An ultrasonography-guided reoperative hysteroscopic procedure revealed a sequestered nest of adenocarcinoma of the endometrium in the right cornua. A more recent report by Argall et al<sup>39</sup> contains 6 additional cases of PAEC, but omits pertinent information regarding the type of EA performed, the presence of EC at the time of the procedure, and the nature of each subject's presenting symptoms.

Our current report of 6 cases includes 4 instances of PAEC after a GEA procedure and reflects the shift from REA to GEA techniques. With the addition of these 6 cases, there are now 35 cases that have been described in the English literature, to our knowledge, 22 reported by AlHilli et al,<sup>24</sup> 6 by Argall et al,<sup>39</sup> and 1 reported by the author (MW).<sup>32</sup> Of these 35 cases, only 24 contain sufficient material for analysis<sup>24,32</sup>: 17 reported by AlHilli et al,<sup>24</sup> 1 in a previous report by one of the authors (MW),<sup>32</sup> and the 6 in this report.

Since the early days of EA, surgeons have expressed concerns that EA might affect the subsequent development of EC. Neuwirth et al<sup>25</sup> assessed the incidence of EC after EA in a population of 509 women with abnormal perimenopausal bleeding and detected neither an increased nor reduced risk of EC in REA-treated women compared to those in the U. S. SEER database.<sup>36</sup> However, Neuwirth investigated only REA-treated women at low-risk for developing EC as subjects with a history of obesity, chronic anovulation, and diabetes were excluded. Krogh et al<sup>40</sup> reported 11 years' follow-up

data on 421 women who underwent transcervical resection of the endometrium (TRCE) from 1990 through 1996 and demonstrated a less-than-expected incidence of EC. However, the study provided an insufficient surveillance period and was composed of a group of women whose average age was  $56 \pm 6$  years, well short of the mean age at which EC typically presents. Finally, a more recent study by Singh et al<sup>41</sup> conducted in the United Kingdom included 1521 women who underwent various types of EA procedures between 1994 and 2011 and noted that none of the women in this retrospective observational study developed EC during the surveillance period. Their suggestion that EA may even have a protective effect on the development of EC is unsupported by their data and the study's design. It appears, however, that the present literature does not indicate an obvious deleterious effect on the incidence of EC in an EA-treated population. However, studies involving a large cohort of women undergoing GEA techniques with a sufficient period of observation have yet to be reported.

Other others have expressed concern that EA may affect the clinical presentation of EC and have questioned what the EA-to-EC interval, or latency period, might be.<sup>22,-24,32</sup> Reports<sup>18,24</sup> have confirmed that EC may present with new-onset vaginal bleeding, pelvic pain, or both, whereas some cases may be entirely asymptomatic.<sup>18,24</sup> In AlHilli's report,<sup>24</sup> excluding 2 patients with EC at the time of the ablation, the latency period averaged 3.9 years (6 months to 10 years). Argall et al<sup>39</sup> reported a similar interval in the 2 subjects who were diagnosed with EC 34 and 60 months after EA. In our present series the EA–EC interval averaged 8.8 years and varied from 5 to 17 years; far lengthier than has been observed. The combination of atypical presenting symptoms and the long latency period is likely to be the source of a diagnostic challenge, particularly in the postmenopausal woman who presents with acute pelvic pain unaccompanied by vaginal bleeding many years after the EA. In the absence of vaginal bleeding, PAEC may be unintentionally excluded from the differential diagnosis—particularly if the evaluating physician is not a gynecologist. Also troubling is that 3 of the 24 (12.5%) subjects described to date were entirely asymptomatic at the time of their cancer diagnosis, which raises concerns that these patients may have eventually presented at a more advanced stage once they became symptomatic.

Another concern is that EA may alter the utility of diagnostic tests, such as endometrial biopsy or transvaginal sonography. Although Argall et al<sup>39</sup> indicated that “endometrial ablation artifact does not appear to hinder evaluation and treatment planning in the presence of endometrial cancer,” several surgeons have expressed concern that EA-induced intrauterine synechiae and endometrial sequestration may obscure and delay its diagnosis.<sup>22,23,17,-21</sup> This fear was underscored by Ahonkallio et al<sup>21</sup> who demonstrated that endometrial biopsy failed in 23% of women with a previous EA and was likely unreliable in many of the remaining subjects, given the sequestration of endometrium in the uterine cornua and elsewhere. AlHilli et al<sup>24</sup> note that “that endometrial sampling and investigation of abnormal uterine bleeding [after EA] may be difficult to perform, yet are feasible and often of high yield.” They note that “only in 2 cases (11.8%) was a preoperative diagnosis with hysteroscopy or endometrial biopsy not successful at presentation because of cervical stenosis and intrauterine adhesions, respectively.” In contrast, the limitations of traditional endometrial biopsy are clearly demonstrated in this report in which endometrial biopsy was attempted in 5 of the 6 subjects. A biopsy attempt in case 1 failed, and RHS was necessary in cases 2 and 5. In case 6 the diagnosis of EC was established only with the adroit maneuvering of a small-diameter hysteroscope. Only in case 4 was a traditional endometrial biopsy successfully performed. These findings in our series may reflect the fact that the ablation-to-cancer interval that we observed is substantially longer than has been reported and

may have allowed additional scarring, contracture, and sequestration to occur. Our observations support the contention by Ahonkallio et al<sup>21</sup> that traditional means of evaluating the endometrial cavity are often obviated, or at least challenging, in the postablation population. The limitations of sonography as a screening tool for postablation EC has been addressed by Morelli et al<sup>42</sup> who concludes that, in the absence of studies that define a standardized endometrial pattern after EA, transvaginal ultrasonography is of limited use in evaluating EA-treated women with postmenopausal bleeding. They recommend that women in whom the ultrasonogram indicates an echogenic or echolucent collection within the uterus undergo hysteroscopic evaluation. However, they provide no guidance regarding how to best address the complexities of endometrial sampling.

One of the authors (MW) has reported the use of sonographically guided hysteroscopic surgery for EA failures.<sup>43,44</sup> This technique produces an excellent specimen of sequestered areas of endometrium that require biopsy and was the method used to diagnose a case reported by one of the authors.<sup>32</sup> However, most physicians will not have access to this method, and hysterectomy may be the only option available to most subjects who require adequate endometrial biopsy for evaluation of signs or symptoms of EC.

The atypical presentation of PAEC and the challenges of endometrial sampling and surveillance have caused some authors to express concerns that EA may delay the diagnosis of EC, causing it to present at a more advanced stage.<sup>17,18,24</sup> However, must be larger prospective long-term studies to adequately understand the effect of EA on the stage at which EC is detected. This longitudinal perspective is particularly relevant as we witness a large cohort of women who have undergone GEA procedures that may affect the endometrial cavity differently from older REA techniques.

## CONCLUSION

Go to:

The United States<sup>28,-31,36</sup> and other developed countries<sup>45,46</sup> are presently witnessing an increasing incidence of EC, reflecting both an aging population<sup>47</sup> and rising obesity rates.<sup>33,48,49</sup>

The United States is projected to experience a doubling in the number of EC diagnoses by the year 2030—to 122,000 cases per annum.<sup>28,-30</sup> Such a doubling of the age-standardized incidence of EC has already been observed in Korea in recent years.<sup>45,46</sup> Simultaneously, the widespread implementation of EA in the United States<sup>14,15,26</sup> and other industrialized countries within the past 20 years means that a large population of EA-treated women, now entering their sixth and seventh decades of life, are at an increasing age-related risk of developing EC. Several researcher-surgeons have suggested<sup>24,25,40,41</sup> that EA does not affect the stage at which EC presents. However, the increasing use of this modality and the shift from NREA to global EA requires larger prospective long-term studies to adequately understand this question.

This cohort of postablation patients will pose at least 2 challenges for physicians. First, we must recognize that AUB may no longer be the primary symptom of PAEC,<sup>32,36</sup> in that a significant number of women are likely to present with pelvic pain, whereas others may remain asymptomatic in the earliest stages of the disease. Second, the conventional methods to evaluate suspected cases of EC, transvaginal ultrasonography and endometrial biopsy appear to be inadequate tools after EA. While ultrasonography-guided reoperative hysteroscopic surgery<sup>43,44</sup> may provide a useful investigative tool for PAEC, it remains a highly skill-dependent technique and is unlikely to gain widespread acceptance.

In lieu of these techniques, it is likely that many women exhibiting signs or symptoms of PAEC will require hysterectomy to properly diagnose and manage the condition.

Our specialty is challenged to better understand the impact of EA on the subsequent occurrence and detection of EC. Whether or not the development of popular GEA devices significantly alters the manner in which EC presents is poorly understood. As far back as 1991 McLucas<sup>50</sup> suggested that women who underwent EA “should be encouraged to undergo a baseline ultrasound three months after ablation and then annually as part of their health maintenance.” Indeed, this has been one of the authors' practice (MW) ever since and has allowed the detection of asymptomatic areas of endometrial regrowth and hematometra. Whether this is a worthwhile and cost-effective practice for the early detection of EC remains unknown. However, the use of ultrasonography annually deserves consideration in women with significant risk factors for the development of PAEC.

Amidst these unknowns, gynecologists are encouraged to conduct careful preablation screening. A proper preoperative evaluation should include a careful history, transvaginal sonography, hysteroscopically directed endometrial biopsy, and a review of the patient's risk factors for developing PAEC. In the lead author's opinion (MW) the importance of hysteroscopically directed endometrial biopsy cannot be overstated, as many significant lesions are focal.<sup>51</sup> Subjects with obesity, anovulatory bleeding, or a history of breast cancer or tamoxifen use should be aware of the increased risk for developing PAEC and the diagnostic challenges of this entity. In many instances, alternative treatment modalities must be offered and strongly recommended for their AUB.

### Contributor Information

Go to:

Morris Wortman, The Center for Menstrual Disorders, Rochester, New York, USA and Clinical Associate Professor of Obstetrics and Gynecology University of Rochester School of Medicine.

George A. Vilos, The Fertility Clinic, Western University, London, Ontario, Canada.

Angelos G. Vilos, The Fertility Clinic, Western University, London, Ontario, Canada.

Basim Abu-Rafea, The Fertility Clinic, Western University, London, Ontario, Canada.

Wendy Dwyer, Clinical Instructor of Obstetrics and Gynecology, University of Rochester, Rochester, New York, USA.

Robert Spitz, Private practice. New London, Connecticut, USA.

### References:

Go to:

1. Duhrrsen. Steam in the Treatment of Uterine Hemorrhage. *Berliner klin Wochenschrift*. [*Berline kiln Weekly*] 1989;36:487–488.
2. Bardenheuer FH. Elextrokoagulation der Uterusschleimhaut zur behandlung kilimakterischer blutungen. [Electrocoagulation of the uterine mucosa for treatment of menopausal bleeding]. *Zentralbl Gynakol* [*Central Sheet for Gynecology*] 1937;4:209–211.
3. Baumann A. Ueber die elektrokoagulation des Endometriums soie der Zervikalschleimhaut [On the electrocoagulation of the endometrium and the cervical mucous membrane]. *Geburtshilfe Frauenheilkd* [*Obstetrics and Gynecology*] 1948;8:221–226.

4. Schulze M. Menorrhagia: the results of radium treatment: a follow-up study. *Cal West Med.* 1937;47:101–106. [[PMC free article](#)] [[PubMed](#)]
5. Cahan W, Brockunier A. Cryosurgery of the uterine cavity. *Am J Obstet Gynecol.* 1967;99:138–153. [[PubMed](#)]
6. Droegemueller W, Greer B, Makowski E. Cryosurgery in patients with dysfunctional uterine bleeding. *Obstet Gynecol.* 1971;38:256–258. [[PubMed](#)]
7. Goldrath MH, Fuller TA, Segal S. Laser photovaporization of the endometrium for treatment of menorrhagia. *Am J Obstet Gynecol.* 1981;140:14–19. [[PubMed](#)]
8. DeCherney A, Polan ML. Hysteroscopic management of intrauterine lesions and intractable uterine bleeding. *Obstet Gynecol.* 1983;61:392–397. [[PubMed](#)]
9. Vancaillie TG. Electrocoagulation of the endometrium with the ball-end resectoscope. *Obstet Gynecol.* 1989;74:425–427. [[PubMed](#)]
10. Arieff AI, Ayus JC. Endometrial ablation complicated by fatal hyponatremic encephalopathy. *JAMA* 1993;270:1230–1232. [[PubMed](#)]
11. Baggish MS, Brill AI, Rosensweig B, Barbot JE, Indman PD. Fatal acute glycine and sorbitol toxicity during operative hysteroscopy. *J Gynecol Surg.* 1993;9:137–143.
12. Daniels JP. The long-term outcomes of endometrial ablation in the treatment of heavy menstrual bleeding. *Curr Opin Obstet Gynecol.* 2013;25:320–326. [[PubMed](#)]
13. Glazerman LR. Endometrial ablation as treatment of heavy menstrual bleeding. *Surg Technol Int.* 2013;23:137–141. [[PubMed](#)]
14. U. S. benign uterine conditions therapy systems market. Report No. A470 Bedminster, NJ: Elsevier Business Intelligence; Exhibit 1–3 pp 1–14.
15. U.S. Thermal Devices Market. Life Science Intelligence. 2012 analysis; forecasts through 2016. <http://lsintel.com/market-reports-page.php?id=A562> Accessed October 29, 2016.
16. Jason D, Wright MD, Thomas J, et al. Nationwide trends in the performance of inpatient hysterectomy in the United States. *Obstet Gynecol.* 2013;122:233–241. [[PMC free article](#)] [[PubMed](#)]
17. McCausland AM, McCausland VM. Long-term complications of minimally invasive endometrial ablation devices. *J Gynecol Surg.* 2010;26:133–149.
18. Wortman M, Cholkeri A, McCausland A, McCausland V. Late-onset endometrial ablation failure: etiology. *Treat Prevent J Minim Invasive Gynecol.* 2015;22:323–331. [[PubMed](#)]
19. Longinotti MK, Jacobson GF, Hung YY, Learman LA. Probability of hysterectomy after endometrial ablation. *Obstet Gynecol.* 2008;112:1214–1230. [[PubMed](#)]
20. Munro MG. ACOG practice bulletin: endometrial ablation. *Obstet Gynecol.* 2007;109:1233–1247. [[PubMed](#)]
21. Ahonkallio SJ, Liakka AK, Martikainen HK, Santala MJ. Feasibility of endometrial assessment

- after thermal ablation. *Eur J Obstet Gynecol Reprod Biol.* 2009;147:69–71. [[PubMed](#)]
22. DeCherney AH, Diamond MP, Lavy G, Polan ML. Endometrial ablation for intractable uterine bleeding: hysteroscopic resection. *Obstet Gynecol.* 1987;70:668–670. [[PubMed](#)]
23. McCausland AM, McCausland VM. Long-term complications of endometrial ablation: cause, diagnosis, treatment and prevention. *J Minim Invasive Gynecol.* 2007;14:399–406. [[PubMed](#)]
24. AlHilli MM, Hopkins MR, Famuyide AO. Endometrial cancer after endometrial ablation: systematic review of the medical literature. *J Minim Invasive Gynecol.* 2011;18:394–400. [[PubMed](#)]
25. Neuwirth RS, Loffer FD, Trenhaile T, et al. The incidence of endometrial cancer after endometrial ablation in a low-risk population. *J Am Assoc Gynecol Laparosc.* 2004;11:492–494. [[PubMed](#)]
26. Hologic's NovaSure System reaches a significant milestone: over two million women have chosen the NovaSure procedure to address the problem of heavy periods. Press release. Bedford, MA: Hologic, Inc., April 22, 2014. Available at: <http://investors.hologic.com/2014-04-22-Hologics-NovaSure-System-Reaches-a-Significant-Milestone-Over-Two-Million-Women-Have-Chosen-the-NovaSure-Procedure-to-Address-the-Problem-of-Heavy-Periods/> Accessed April 2, 2017.
27. A Complete Guide to NovaSure Endometrial Ablation. Bedford, MA: Hologic Corp., 2015. Available at: [http://www.novasure.com/sites/novasure/files/NovaSure\\_Physician\\_Brochure\\_2015\\_1.pdf](http://www.novasure.com/sites/novasure/files/NovaSure_Physician_Brochure_2015_1.pdf) Accessed April 2, 2017.
28. McAlpine JN, Temkin SM, Mckay HJ. Endometrial cancer: not your grandmother's cancer. *Cancer* 2016;122:1787–1798. [[PubMed](#)]
29. Rahib L, Smith BD, Aizenberg R, Rosenzweig AB, Fleshman JM, Matrisian LM. Projecting cancer incidence and deaths to 2030: the unexpected burden of thyroid, liver, and pancreas cancers in the United States. *Cancer Res.* 2014;74:2913–2921. [[PubMed](#)]
30. Torre LA, Bray F, Siegel RL, Ferlay J, Lortet-Tieulent J, Jemal A. Global cancer statistics, 2012. *CA Cancer J Clin.* 2015;65:87–108. [[PubMed](#)]
31. Cancer Statistics Center. Uterine Corpus. Atlanta, GA: Atlanta: American Cancer Society; Undated. Available at: <https://cancerstatisticscenter.cancer.org/#/cancer-site/Uterine%20corpus/> Accessed October 16, 2016.
32. Wortman M, Dawkins JC. Post-ablation endometrial carcinoma (PAEC) following radiofrequency endometrial ablation: a case report and its implications for management of endometrial ablation failures. *Surg Technol Int.* 2016;24:161–166. [[PubMed](#)]
33. Weiderpass E, Persson I, Adami HO, Magnusson C, Lindgren A, Baron JA. Body size in different periods of life, diabetes mellitus, hypertension, and risk of postmenopausal endometrial cancer (Sweden). *Cancer Causes Control.* 2000;11:185–192. [[PubMed](#)]
34. Gehrig PA, Bae-Jump VL, Boggess JF, Groben PA, Fowler WC, Jr, Van Le L. Association between uterine serous carcinoma and breast cancer. *Gynecol Oncol.* 2004;94:208–211. [[PubMed](#)]
35. Early Breast Cancer Trialists' Collaborative Group (EBCTCG). *Lancet.* 2005;365:1687–1717.



[PubMed]

36. National Cancer Institute. Cancer Stat Facts: Endometrial Cancer. Frederick MD: NIH, NCI, undated. Available at: <http://seer.cancer.gov/statfacts/html/corp.html> Accessed March 25, 2017.
37. Copperman AB, DeCherney AH, Olive DL. A case of endometrial cancer following endometrial ablation for dysfunctional uterine bleeding. *Obstet Gynecol.* 1993;82:640–642. [PubMed]
38. Margolis MT, Thoen LD, Boike GM, Mercer LJ, Keith LG. Asymptomatic endometrial carcinoma after endometrial ablation. *Int J Gynecol Obstetr.* 1995;51:255–258. [PubMed]
39. Argall E, Jovanovic A, Figueroa R, Mayer A, Nelson B, Roland P. Effects of endometrial ablation on treatment planning in women with endometrial cancer. *J Minim Invasive Gynecol.* 2016;23:281–285. [PubMed]
40. Krogh RA, Lauszus FF, Guttorm E, Rasmussen K. Surgery and cancer after endometrial resection: long-term follow-up on menstrual bleeding and hormone treatment by questionnaire and registry. *Arch Gynecol Obstet.* 2009;280:911–916. [PubMed]
41. Singh M, Hosni MM, Jones SE. Is endometrial ablation protective against endometrial cancer?—a retrospective observational study. *Arch Gynecol Obstet.* 2016;293:1033–1037. [PubMed]
42. Morelli M, Rocca ML, Mocciano R, et al. Sonographic findings in postmenopausal women with a prior endometrial ablation: interpretation and management of women with endometrial thickening and bleeding. *J Minim Invasive Gynecol.* 2015;22:489–494. [PubMed]
43. Wortman M, Daggett A, Deckman A. Ultrasound-guided reoperative hysteroscopy for managing global endometrial ablation failures. *J Minim Invasive Gynecol.* 2014;21:238–244. [PubMed]
44. Wortman M. Ultrasound-guided reoperative hysteroscopy: managing endometrial ablation failures. *Surg Technol Int.* 2012;22:165–171. [PubMed]
45. Lim MC, Moon EK, Shin A, et al. Incidence of cervical, endometrial, and ovarian cancer in Korea, 1999–2010. *J Gynecol Oncol.* 2013;24:298–302. [PMC free article] [PubMed]
46. Jung KW, Won YJ, Oh CM, et al. Prediction of cancer incidence and mortality in Korea, 2016. *Cancer Res Treat.* 2016;48:451–457. [PMC free article] [PubMed]
47. Mertz L. The coming gray tide: wanted: health innovations for an increasingly older population. *IEEE Pulse.* 2017;8:6–11. [PubMed]
48. Busch EL, Crous-Bou M, Prescott J, et al. Endometrial cancer risk factors, hormone receptors, and mortality prediction. *Cancer Epidemiol Biomarker Prev.* 2017;26 In press. [PMC free article] [PubMed]
49. Renehan AG, Soerjomataram I. Obesity as an avoidable cause of cancer (attributable risks). *Recent Results Cancer Res.* 2016;208:243–256. [PubMed]
50. McLucas B. Intrauterine applications of the resectoscope. *Surg Gynecol Obstetr.* 1991;172:425–431. [PubMed]
51. Svirsky R, Smorgick N, Rozowski U, et al. Can we rely on blind endometrial biopsy for detection of focal intrauterine pathology? *Am J Obstet Gynecol.* 2008;199:115.e1–115.e3. [PubMed]



---

Articles from JLS : Journal of the Society of Laparoendoscopic Surgeons are provided here courtesy of  
**Society of Laparoendoscopic Surgeons**