

Sonographically Guided Hysteroscopic Endomyometrial Resection

MORRIS WORTMAN, MD, FACOG
DIRECTOR, CENTER FOR MENSTRUAL DISORDERS
CLINICAL ASSOCIATE PROFESSOR OF GYNECOLOGY
UNIVERSITY OF ROCHESTER MEDICAL CENTER
ROCHESTER, NEW YORK

ABSTRACT

Hysteroscopic endomyometrial resection (EMR) was first reported by this author in 1994.[1] Several refinements have been made through the years including the addition of sonographic guidance as well as its adaptation into an office-based environment. EMR has many outstanding benefits including its adaptability to a "see-and-treat" procedure appropriate to an office setting. Importantly, EMR has a very high rate of hysterectomy avoidance and provides a complete histologic specimen of the endometrium and superficial myometrium. Finally, EMR is a superior method of managing both resectoscopic and non-resectoscopic endometrial ablation failures.

INTRODUCTION

This author first reported endomyometrial resection (EMR) in 1994.¹ EMR, a hysteroscopic technique, involves the removal of long continuous strips of tissue from the uterine fundus to the internal os resulting in a fairly predictable depth of destruction of endomyometrial tissue throughout the cavity. EMR is both qualitatively and quantitatively different from transcervical resection of the endometrium (TCRE) originally reported by Magos et al.,² whose technique aims "to excise tissue to include 1–2 mm of myometrium." The goal of endomyometrial resection is the removal of 4–5 mm of myometrium beyond the endometrial basalis. The differences between the techniques are underscored by average specimen weight (12.3 grams with EMR and 6.67 grams with TCRE), as well as the rates of amenorrhea (85.5% with EMR compared with 25% with TCRE).^{3,4}

In addition to providing excellent outcomes as measured by a high rate of amenorrhea and hysterectomy avoidance in long-term follow-up,³ the procedure obviates the need for medical preparation of the endometrium and expensive disposable equipment. Other advantages include a complete specimen of the endometrium and myometrium for histologic analysis, as well as its easy adaptability to the treatment of endometrial polyps, leiomyomas, and anomalous uteri. Importantly, EMR can

be used to re-treat endometrial ablation and resection failures, avoiding hysterectomy in the vast majority of patients.⁵ Since our first report in 1994, EMR has now evolved to an office-based procedure performed under conscious sedation and continuous sonographic monitoring.

EQUIPMENT, SETUP, AND PERSONNEL

Low-viscosity fluids are delivered through a Dolphin II Hysteroscopy Pump (Gyrus ACMI, Southborough, MA). Fluids are allowed to egress by gravity alone during the resection phase of the procedure. Active suction is supplied throughout the coagulation phase of the procedure in order to remove as many water vapor bubbles as possible. Our O.R. is equipped with an Autocon II 400 (Karl Storz Endoscopy, Culver City, CA), which enables us to employ both unipolar and bipolar electro-surgery (Fig. 1). Unipolar electro-surgery is generally performed at 140 watts of C-Cut, effect 4, during the resection phase and 120 watts of forced coagulation current, effect 4, for the ablation portion of the procedure. Whenever bipolar electro-surgery is used, a saline-C-cut, effect 5 setting is employed.

We stock a variety of continuous flow resectoscopes (CFR) generally employing a 26 Fr CFR. A 22 Fr CFR is used to manage reoperative hys-

terectomy following endometrial ablation and EMR failures. Additionally, a CFR equipped with bipolar working element (Part number CE 0123, Karl Storz Endoscopy, Culver City, CA) and a 24 Fr bipolar cutting loop (Part number 27040GP) is used in selected cases in which excess fluid absorption remains a very real concern.

A Hitachi EUB 420 (Hitachi Medical Systems America, Inc., Twinsburg, OH) equipped with a 3.5 MHz abdominal transducer provides continuous sonographic guidance. Our operating room also has 2 side-by-side monitors (Fig. 1) enabling real-time observation of both the hysteroscopic and ultrasound views. All procedures are digitally recorded using a MediCapture USB 200 (MediCapture, Inc., Philadelphia, PA) (Fig. 2).

All cases require a minimum of 4 assistants in the O.R. The first assistant stands to operator's left while the sonographer stands to the right. A fluid management technician is responsible for all functions related to the hysteroscopy pump, reporting the rate of fluid absorption as well as the net deficit. During office-based procedures a specially trained nurse practitioner or an appropriately credentialed registered nurse administers incremental doses of midazolam and fentanyl while monitoring the patient for her level of consciousness.

PROCEDURE

Patients undergo laminaria placement the day prior to surgery, a critically important step that obviates the complexities of managing intraoperative cervical stenosis. For OBS procedures, patients are asked to not eat or drink anything for a minimum of 4 hours prior to surgery.

The procedure is begun by removing the previously placed laminaria and prepping the cervix and vagina with a bactericidal solution. The cervix is grasped at 12 o'clock with a tenaculum. Next, a vasopressin solution containing 3 units in 20 mL saline is injected deep into the cervical stroma at 3 and 9 o'clock using a 21-gauge x 1½-inch needle. The cervix is dilated, under sonographic guidance, to either 8 mm (for a 22 Fr resectoscope) or 10 mm (for a 26 Fr resectoscope). Glycine 1.5% is delivered through the hys-

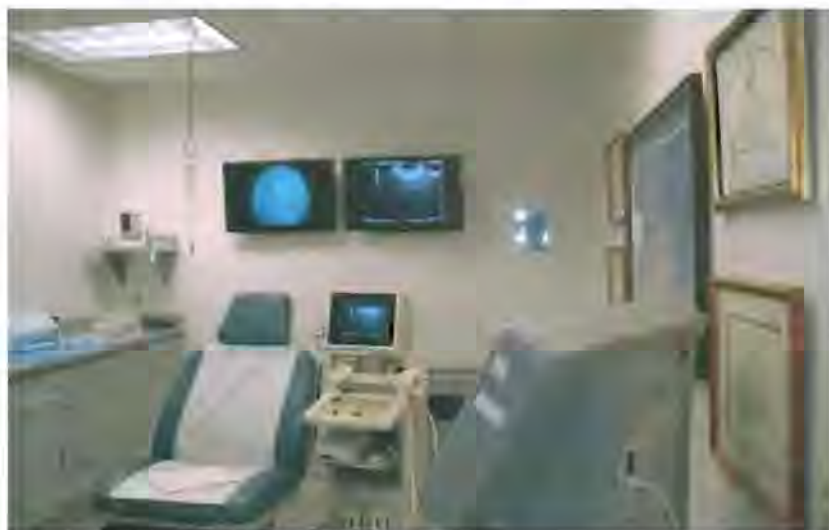

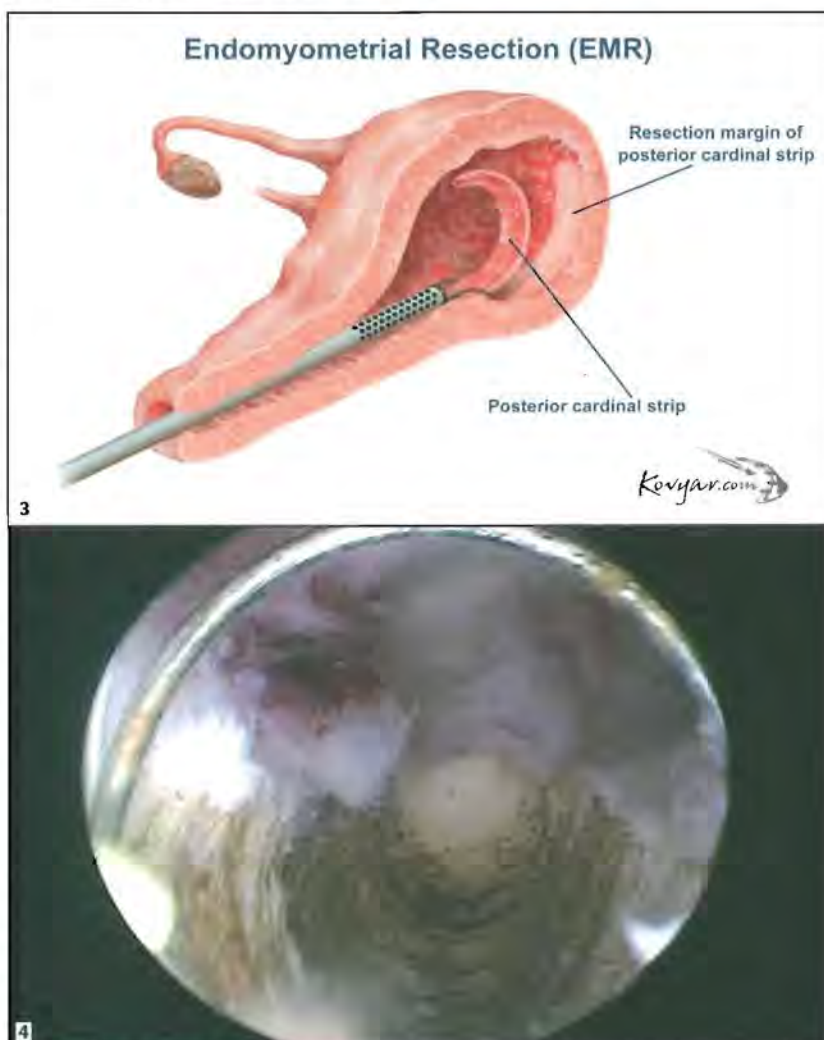
Figure 1. Room setup for hysteroscopic EMR (office-based).

teroscopes pump at an infusion pressure of 120–140 mm Hg. The higher pressures efficiently clear debris from the operative field and allow excellent visualization to be quickly established. The outflow port of the resectoscope is attached only to gravity during the resection phase of the procedure. Infusion pressure is often reduced depending on the rate of fluid intravasation, though most cases are performed with infusion pressures of 100–140 mm Hg. We do not consider the mean arterial blood pressure (MAP) in choosing an infusion pressure as we have found little correlation between MAP and net fluid absorption. Moreover, setting the pressure a level below the MAP often results in poor distention and visualization.

Following an inspection of the uterine cavity, the resectoscope is brought to the posterior wall of the fundus with the loop extended 7–8 mm. This distance correlates very well with the loop occupying half the visual field. With this fixed distance, the cutting current is activated and the entire resectoscope-loop assembly is brought toward the operator until the endocervical glands of the internal os are visualized when the loop is retracted (Figs. 3 & 4). During resection care is taken to keep the loop buried to its full depth so that only the insulation can be seen. The resulting strip of tissue — the posterior cardinal strip — will have a uniform depth and width that corresponds to the architecture of the electro-surgical loop (approximately 6 mm wide and 5 mm deep). Each individual strip of tissue is removed to prevent it from floating freely in the uterus and obscuring the anatomy. The anterior cardinal strip is removed in a similar fashion leaving about 1 cm of tissue untreated at the fundus. In cases involving a previous Cesarean section with resultant thinning of the lower uterine segment, the loop is withdrawn by half, resulting in a very superficial removal — about 2 mm — of the endometrium at that particular point in the dissection. In cases involving extreme thinning of the lower segment, no attempt is made to resect it. The lateral cardinal strips are removed by placing the electrode just proximal to the tubal ostium. In cases involving a prominent uterine septum, one cannot place the loop adjacent to the ostium. In such cases, the loop is simply placed as close to the ostium as possible before the lateral cardinal strips are removed.



Figure 2. Ancillary equipment for hysteroscopic surgery.



Figures 3 and 4. Removal of the posterior cardinal strip.

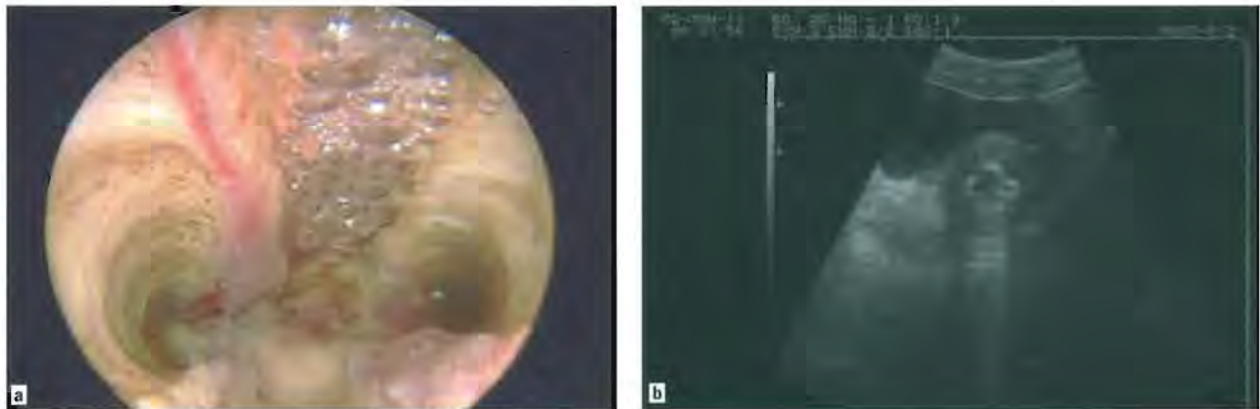


Figure 5. "Four-leaf clover" appearance after removal of all four cardinal strips.

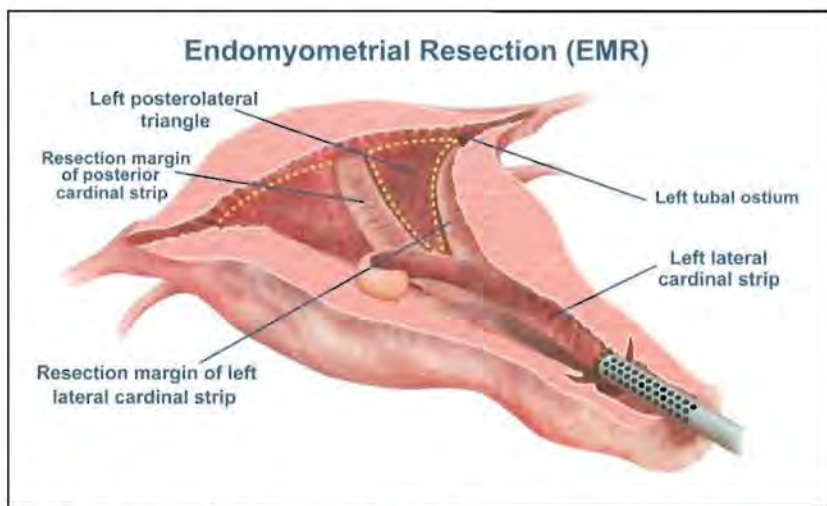


Figure 6. The formation of the left posterolateral triangle.

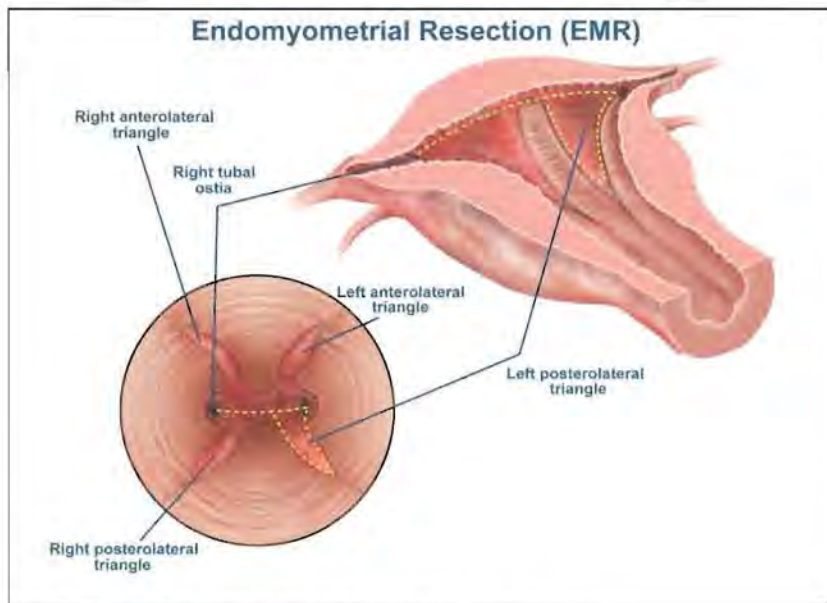


Figure 7. The formation of anterolateral and posterolateral triangles.

Because the uterus naturally tapers from the fundus to the internal os the removal of the four cardinal strips gives the appearance of a four-leaf clover both on ultrasound and hysteroscopically (Fig. 5).

Also, the uterus is now divided into two anterolateral and two posterolateral triangles (Figs. 6 & 7), the size of which will vary directly with the saggital and transverse diameters of the uterus.

Both of the anterolateral (AL) and posterolateral (PL) triangles are removed using the same resection technique. Because one should avoid repeated resection in the same area, the strips of tissue removed from the AL and PL triangles will be shorter in length compared with the cardinal strips. Also, during removal of the proximal tissue it will be necessary to taper the resection so that its overall depth does not exceed that of the adjacent cardinal strips. In this fashion the cardinal strips act as a guide with which to judge the total depth of resection for the entire uterus — excluding the fundus and tubal ostia. Removal of the cardinal strips, the AL and PL triangles, will result in various ridges throughout the uterine cavity. This so-called "ridge tissue" (Fig. 8) can be removed in long, shallow strips so that the overall depth of resection is 4–5 mm, consistent with the depth of the cardinal strips.

All that remains is removal of endometrium from the tubal ostium and fundus. In a series of over 2,400 cases, there have been no perforation or rupture injuries at the tubal ostium — virtually all have been confined to the fundus. Therefore, the next step is to remove tissue around and including the tubal ostia. In those cases in which the uterine contour allows access, a stan-

standard loop can be used. Most of my experience is with the 26 Fr Storz resectoscope (model number 26040 SD) fitted with a 24 Fr loop electrode (Part number 27050G) (Fig. 9), which has a 55-degree angle. Unfortunately, this configuration is often inadequate to resect tissue well up into the cornua. This is especially true in the presence of even a slight uterine septum. It is my practice to bend these loops to an obtuse angle — approximately 155 degrees (Fig. 10) — in order to resect the tissue around the cornua. In still other instances, the loop, in addition to being reconfigured to this angle, must be narrowed to approximately 3–4 mm in order to facilitate dissection into the cornual regions of the uterus. It should be noted that reconfiguring these loops is not approved by the manufacturer. Using an appropriately configured loop, the ostia is then excised to a depth of about 3 mm. Ultrasound scanning is quite useful in visualizing the depth of dissection at this vulnerable portion of the dissection.

After removal of tissue at the ostia, the tissue at the fundus is excised (Fig. 11). In my experience, the fundus is often quite vulnerable to rupture — especially at high intrauterine pressures. I try to remove no more than 4 mm of tissue at the fundus unless the uterine anatomy allows a more liberal dissection. Depending on how much tissue was left at the fundus, this may require one or more sweeps across the fundus.

Finally, having resected the entire endomyometrium down to a depth of at least 4–5 mm (except at the ostia), I use a 3-mm ball-end electrode to deeply coagulate the exposed myometrium at 120 watts of coagulation current. This is done for two reasons: first, to facilitate hemostasis from exposed arterioles and venous sinuses; and second, to provide a

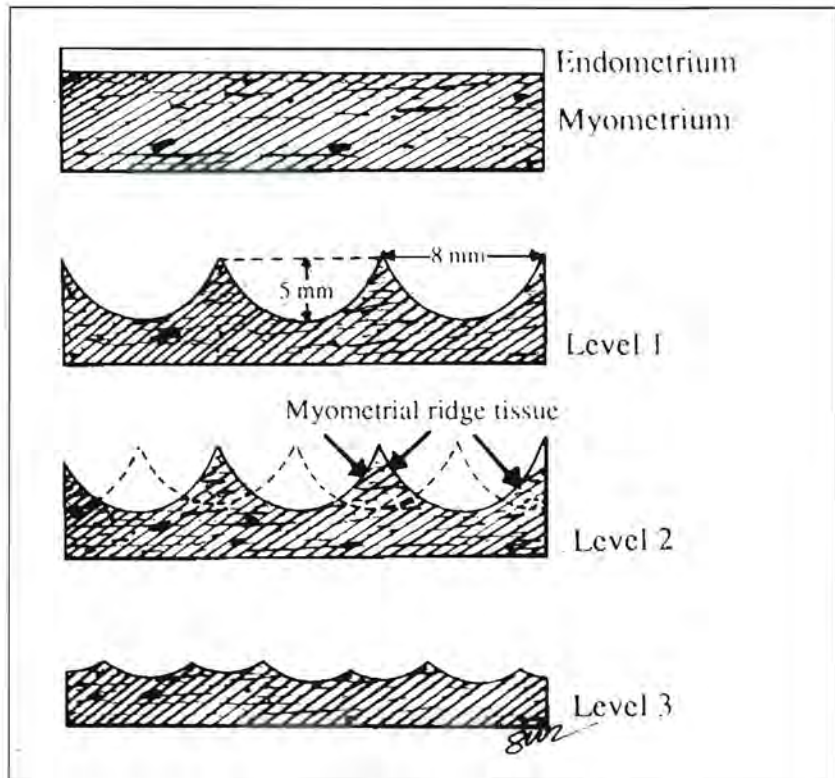


Figure 8. The formation and removal of "ridge tissue."

deeper margin of endometrial destruction that may exist in sequestered islands of adenomyotic tissue. Yet another benefit of coagulation is that one can use this opportunity to smooth out the resection to a uniform depth by coagulating the remnants of ridge tissue. I generally coagulate beginning with either the posterior or lateral walls followed by the anterior wall tubal ostia and fundus. It is important to actively remove water bubbles that form and adhere to the anterior uterine wall utilizing active suction. This is done to minimize the possibility of gas emboli,⁶ a rare but serious complication of hysteroscopic surgery.

Special Considerations for the Woman with a Previous Cesarean Section

A previous Cesarean section scar is often seen at the time of hysteroscopy. Despite a recent report by Shih, Chang, et al.,⁷ it is doubtful that the defects seen with previously reported Cesarean sections are a common cause of prolonged vaginal bleeding. If the uterine wall thickness in the lower segment is greater than 7 mm, I generally excise no more than 2–3 mm. If the uterine wall thickness is less than 7 mm, I generally coagulate or fulgurate any visible endometrium. In rare

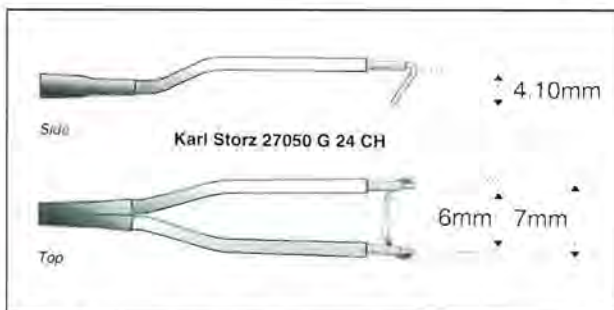


Figure 9. Dimensions of a 24 Fr loop electrode (Karl Storz Endoscopy, Culver City, CA).

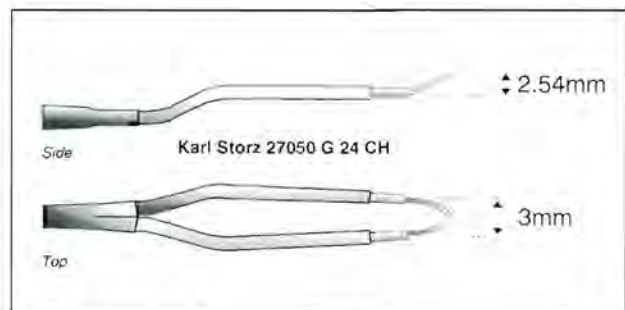


Figure 10. Reconfigured loop electrode.



Figure 11. The appearance of the fundus following its complete resection.

instances, one may notice a pronounced out-pouching in the region of the previous Cesarean section scar nearly precluding adequate treatment of this area altogether.

Special Considerations for Managing the Septate Uterus

Small uterine septums are quite common and require no adjustments to the procedure. However, the presence of a deep uterine septum does require special attention as it will both inhibit adequate continuous flow in the portion of the uterus divided by the septum and preclude access to the tubal ostia. Therefore, in the presence of a large septum, one should resect it to the extent necessary in order to establish continuous flow, obtain good visualization, and excise the tissue around the tubal ostia. The importance of ultrasound guidance and a gentle resection technique cannot be overstated.

Uterine Rupture Versus Uterine Perforation

Uterine rupture is an entity quite distinct from uterine perforation. Uterine perforation occurs when an implement such as either a cervical dilator or electrode is passed through

the uterine serosa. According to Brooks, the passage of an active electrode through the uterus warrants either an exploratory laparotomy or laparoscopy.³ Although the management of such cases has been debated,^{8,9} it is clear that not all defects that are discovered during hysteroscopic surgery are the result of perforation. The author has witnessed numerous uterine defects, varying from 2–10 mm, that occur when the hydrostatic pressure within the uterus is enough to overcome the integrity of its seromuscular layer once its tensile strength has been weakened by the resection process. In the author's personal series of 304 cases, we reported 7 cases of uterine rupture (2.3%).³ Both uterine rupture and perforation cause a rapid loss of intrauterine pressure coupled with an apparent increase in fluid deficit. In either event, the case should immediately cease. If the site of the uterine defect is unknown, one may distend the uterus with normal saline in order to locate the defect.

Once the location of the defect is ascertained, the instruments are then removed from the patient. Our practice has been to replay the procedure on the digital recorder. The use of an "instant

replay" often clarifies the sequence of events and helps distinguish uterine rupture from uterine perforation. In our own series, uterine rupture is a far more common event and often presents as one of two distinct scenarios.

In the first scenario, rupture occurs during removal of tissue at the fundus—generally to one side of the midline. A slow-motion replay often reveals that the rupture occurs well *after* the active electrode has passed through the operative field. In the second instance, there is a sudden loss of pressure and visualization while working in one portion of the uterus only to discover that the defect occurred in another portion. If one of these two scenarios occurs, we recommend that one not proceed to a laparoscopy or laparotomy; instead, the patient should be carefully monitored. In 20 years of performing more than 2,400 EMR procedures, the author has yet to encounter a case in which a laparoscopy or laparotomy was necessary. And though uterine ruptures occur in approximately 2% of our patients, we have thus far never observed an injury to the pelvic viscera.

Combining Endomyometrial Resection with Myomectomies

About one-third of EMRs are associated with the removal of submucous or intramural leiomyomas. Concomitant myomectomies add an additional level of complexity to EMR. Along with increased operative times, the combination of EMR and myomectomies is associated with an increased incidence of fluid extravasation and postoperative bleeding. A thorough discussion of managing leiomyomas at the time of EMR is beyond the scope of this article.

CONCLUSIONS

Sonographically guided EMR is a superior method for the minimally invasive management of AUB. It provides a known depth of endometrial destruction and, in experienced hands, can be used to re-treat failures of any other endometrial ablation technique. Its advantages include a complete histologic specimen of the endometrium and myometrium, obviating the need for a separate biopsy. EMR is adaptable to a wide range of anatomic variations including leiomyomas as well as congenital anomalies. In a series of 304

women followed for a mean of 31.8 ± 22.1 months (range 6–75 months), we observed that 85.5% of patients were amenorrheic. Reoperative hysteroscopic surgery was required in 4.3% of subjects while 5.0% underwent subsequent hysterectomy because of method failure. These data are unmatched by any other endometrial ablation or resection technique described to date.³

Despite the success of endomyometrial resection, there are relatively few reported series in the medical literature. Unlike non-resectoscopic ablation techniques, EMR is highly skill dependent and requires a committed O.R. team. Its mastery however provides superior outcomes for patients with comparatively low rates of subsequent hysterectomy and re-treatment. **ST**

AUTHORS' DISCLOSURES

The author has no financial relationships to disclose.

REFERENCES

1. Wortman M, Daggett A. Hysteroscopic endomyometrial resection: a new technique for the treatment of menorrhagia. *Obstet Gynecol* 1994;83:295–98.
2. Magos AL, Baumann R, Turnbull AC. Transcervical resection of the endometrium in women with menorrhagia. *Br Med J* 1989;298:1209–12.
3. Wortman M, Daggett A. Hysteroscopic endomyometrial resection. *JLS* 2004;4:197–207.
4. Magos AL, Baumann R, Lockwood GM, et al. Experience with the first 250 endometrial resections for menorrhagia. *Lancet* 1991;337:1074–8.
5. Wortman M, Daggett A. Reoperative hysteroscopic surgery in the management of patients who fail endometrial ablation and resection. *J Am Assoc Gynecol Laparosc* 2001;8(2):272–7.
6. Munro MG. Complications of hysteroscopic and uterine resectoscopic surgery. *Obstet Gynecol Clin N Am* 2010;37:399–425.
7. Shih CL, Chang YY, Ho M, et al. Hysteroscopic transcervical resection. A straightforward method corrects bleeding related to Cesarean section scar defects. *Am J Obstet Gynecol* 2011;204:278.e1-2.
8. Brooks PG. Complications of operative hysteroscopy: How safe is it? *Clinical Obstet Gynecol* 1992;35:256–61.
9. Wortman M. Complications of Hysteroscopic Surgery. In: Isaacson K (ed), *Complications of Gynecologic Endoscopic Surgery*. Philadelphia: Saunders; pp 185–200, 2006.